

Infections of the fingers and hands

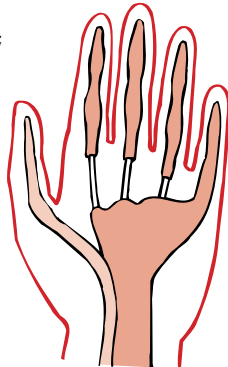
Fishermen are particularly prone to infections of the hands and fingers because of their working environment and the things that they are required to handle during their work. For instance, they may be injured by fish spines and bones, by broken ends of warps and many other things. Minor cuts and grazes often go unnoticed at the time of injury. Bacteria are carried into these wounds from fish slime and guts and also from pieces of metal etc. Infection then develops with inflammation of the infected area and the formation of pus.

Prevention is always better than cure and it is recommended that Chlorhexidine Gluconate 20% (HIBISCRUB) is used to wash hands and forearms after handling fish of any kind. The Hibiscrub can be used as a soap or in solution.

Hand anatomy is very complex but two features are relevant to fishermen:

- The tissues of the tips of the fingers (the finger pulps) are completely closed off from the tissues of the remainder of the fingers. Because of this, infection and the formation of pus in the finger tip causes a great deal of swelling and pain. This situation is called a pulp space infection.
- The hand tendons (which move the fingers) are enclosed either partially or completely in sheaths (Fig 8.1). A finger infection may spread along the tendon sheath towards the communal sheath in the palm. This is particularly likely when the little finger or thumb is the infected part. Infection of the palm sheath causes severe pain and swelling of the hand. This is a palmar space infection.

Figure 8.1 Tendons of the hand; the tendon sheath does not cover all of the middle three tendons.



All finger and hand infections are very painful and disabling. Some can cause permanent disability. They should be treated aggressively if they occur but it is preferable to prevent them. Finger and hand infections can be avoided by:

- Thorough washing of the hands at the end of every work period, preferably with chlorhexidine gluconate 20% (HIBISCRUB).
- Prompt treatment and cleaning of all minor cuts, scratches and abrasions.
- Aggressive early treatment including antibiotics if throbbing pain or inflammation is noted anywhere in the hands or fingers

Infections of the fingers and hands

Cuts to the hands (including tendon injuries)

Salt water boils (pips or pigeons)

Jumbo wrist

Tit juice conjunctivitis (fisherman's conjunctivitis)

Fish erysipeloid (fish poisoning)

Dogger Bank itch (curly weed rash)

Removing a fish hook

Specific hand and finger infections

Boils

Boils can occur on any part of the hands or fingers. They are often more painful than boils elsewhere on the body because the skin on fishermen's hands is hard and thick and unable to give. Boils therefore take a long time to come to a head and discharge.

To treat boils, a clean, dry dressing should be applied to the area. Antibiotics should be given if there is any evidence of spreading infection (e.g. redness going up the arm)

Pulp space infections

These are usually caused by fish bones or spines or by fragments of wire. They cause severe throbbing pain of the finger tip and require urgent treatment. The patient should be given antibiotics and the pus must be released by incision using a scalpel. If possible the patient should be landed, but if this is not possible, the finger should be numbed using local anaesthetic (Lignocaine 1%) and the palmar surface of the finger incised down to bone in the line of the finger. Pus will be released in this way. The finger should then be dressed and the patient landed.

Nail fold infections

These are also called whitlows. They are usually caused by minor scratches around the finger nails. The skin around the nail becomes painful and swollen. As soon as the infection is suspected it should be treated with oral antibiotics. If the infection comes to a head with pus present, the finger should be numbed with local anaesthetic (Lignocaine 1%) and a small incision should be made in the ballooned skin over the pus. The finger should then be dressed and the patient landed.

Palmar space infections

These are infections of the deep structures of the hand and must be taken very seriously. They are usually caused by an extension of a deep infection of a finger or of an infection of the tendon sheath of the thumb or little finger. They can also be caused by a prick in the palm or a stab wound from a knife in the palm. The most common cause is a finger infection which has been ignored.

The whole hand becomes swollen, there is severe throbbing pain and this is made worse by any movement of the fingers. The patient feels generally unwell, with sweating, shivering, sickness and raised body temperature all being possible. Treatment is urgent to prevent permanent disability. The patient must be put to bed with the hand elevated and arrangements must be made to land the patient as soon as possible. Antibiotics must be given, ideally by injection, until the patient is landed. If in doubt, seek **RADIO MEDICAL ADVICE**.

Lymphangitis

This is infection and inflammation of the lymph channels and commonly occurs as a result of finger and hand infections. It is seen as red lines spreading up the arms. See Figure 8.2 for the pathways along which infection passes up the arms. As well as fiery red lines up the arms the lymph glands at the elbow and in the armpits may become swollen and painful. If lymphangitis appears, there is infection in the hand until proven otherwise and the patient should be given antibiotics even if there is no obvious source of the infection.

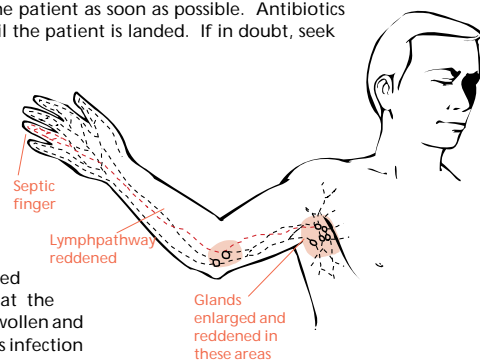


Figure 8.2 Lymphangitis – septic finger.

Haddock Rash

This is an infection of the clefts between the fingers that occurs following gutting white fish, particularly haddock. Untreated it can cause redness, pain and swelling for several weeks. It usually responds rapidly to antibiotics, given for five days.

Cuts to the hands (including tendon injuries)

All cuts to the hands should be taken seriously due partly to the high risk of infection from even minor wounds (see above).

All cuts to the hands and fingers should also raise the possibility of injury to the tendons or nerves. If the patient is unable to move his fingers normally himself or has reduced sensation in a finger, there is possible tendon or nerve damage and the patient needs to be landed for possible surgery.

Salt water boils

These are also called pips or pigeons. They occur because the cuffs of clothing worn by fishermen rub the sand and grit brought up in nets into the skin of the wrists and the back of the hands causing tiny abrasions. The cuffs are usually covered with fish slime from sorting and gutting operations and bacteria in the slime infect the abrasions. Sores appear as small irritating spots which soon become tiny painful septic blisters. Some become large boils and the whole of the wrist and back of the hand may become inflamed, hard and painful.

The sores can be prevented by thoroughly washing the hands and wrists after coming off watch and by frequently scrubbing the cuffs of waterproof coats with soap and fresh water. When sleeve cuffs become cracked and worn, the garment should be replaced.

Once the sores occur, they should be bathed frequently in warm water and covered with a dry dressing. If boils develop the patient should be given antibiotics.

Jumbo Wrist

The medical term for this condition is Fishermen's tenosynovitis of the wrist. It occurs because prolonged repetitive movements of the wrist can cause inflammation of the sheaths through which the tendons around the wrist move. It is fairly common when fishermen are involved in prolonged gutting or when they return to sea after a long period ashore. Wrist movement (as occurs in gutting) causes localised pain and a sensation of fine grating. This grating (known also as crepitus) can be felt by placing the palm of the examiner's hand lightly over the painful place and asking the patient to carry out the painful movements.

The condition can be treated with anti-inflammatory drugs (e.g. Diclofenac or Ibuprofen) but often fails to settle whilst the fisherman continues to work. The most effective treatment is complete rest for a period of 10 – 14 days, preferably with the wrist supported in a splint.

Tit juice conjunctivitis (fishermen's conjunctivitis)

This is an acute inflammation of the conjunctiva (the thin lining membrane over the eyes) due to contact with the juice of 'duffs' or 'tits'. These are marine growths which look like suet dumplings with finger-like growths protruding from them. When they are trawled up they may burst in the cod end of the net and the juice, which contains tiny sharp silicon particles, may be squirted into the eyes of the fisherman. It is very irritant to the eyes, causing redness and inflammation and eventually blistering. The eyes are very painful and this is made worse by exposure to light. If untreated the eyes may close due to swelling.

The treatment is to wash out the eyes with large amounts of clean, fresh water. Relief from the pain can be obtained by instilling eye drops (Betamethasone and Neomycin eye drops four times daily). The eyes must be examined by a doctor on return to port.

Fish erysipeloid (fish poisoning)

This arises from minor pricks or scratches caused by the bones or fins of fish. Particles of fish or infected fish slime are carried into the wounds. Inflammation starts as a small red area, the margins of which become swollen and purple. The inflammation and discoloration spread rapidly up the arms. The margin remains purple and raised whilst the centre appears only mildly inflamed. The whole area is swollen and tender and may itch or burn. Lymphangitis (see above) may occur.

The disease can be prevented by thorough washing with soap and hot water at the end of every watch. When the disease is diagnosed, treatment should be started with antibiotics.

Dogger Bank Itch (curly weed rash)

This is an allergic skin condition caused by contact with a seaweed-like plant, known to fishermen as curly weed, which grows in the shallow waters of the North Sea, especially around the Dogger Bank area. It is also found around Scotland, Norway and Greenland. Not all fishermen in contact with curly weed develop the rash or become sensitised. Sensitisation can be very gradual but once established it requires only contact with nets used in the area to precipitate an attack.

The rash usually appears as a dermatitis on the backs of the hands, wrists and forearms. Once the allergy is established further contact causes the rash to spread to the face and eyes and ultimately to the whole body. The affected parts are itchy, red and swollen. Weeping and drying can cause painful cracks to appear in the skin. When the face and eyes are affected there is marked swelling around the eyes.

The only effective treatment is to remove the patient from all further contact with curly weed. He will need to change to deep water ships. The rash usually clears up on going ashore but in established cases drug treatment may be required. The patient is given antihistamines. These drugs cause sleepiness; the patient must not be allowed to operate machinery whilst on these drugs. Steroid ointment (Hydrocortisone 1% cream) should be applied to the affected parts. Inflammation of the eyes can be treated with eye drops (Betamethasone and Neomycin eyedrops) and the patient should be landed.

Removing a fish hook

Before attempting to remove the hook, the surrounding area needs to be numbed using an injection of local anaesthetic (Lignocaine 1%). Once the area is numb (usually the finger) the hook and the area of skin around it should be thoroughly cleaned with antiseptic solution.

Feel for the position of the barb and make sure that the area is numb, using some more local anaesthetic if necessary. Grasp the shank of the hook firmly in a pair of pliers. Following the curve of the hook, push the barb through the skin until the barb and part of the hook is visible. Clip off the barb and withdraw the hook, again following the curve of the hook.

The patient should be given antibiotics due to the high risk of infection.

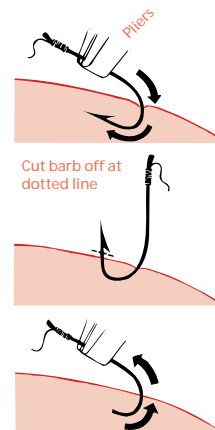


Figure 8.3 Removal of fish hook.